

## The pattern of amyloid deposition in the lung

Lai-Meng LOOI, *FRCPath, FRCPA.*

*Department of Pathology, Faculty of Medicine, University of Malaya, Kuala Lumpur.*

### Abstract

A review of routine histopathological samples and autopsies examined at the Department of Pathology, University of Malaya revealed 15 cases of amyloidosis of the lung. Two were localized depositions limited to the lung while in the remainder, lung involvement was part of the picture of systemic amyloidosis. Both cases of localized amyloidosis presented with symptomatic lung/bronchial masses and a clinical diagnosis of tumour. Histology revealed "amyloidomas" associated with heavy plasma cell and lymphocytic infiltration and the presence of multinucleated giant cells. In both cases, the amyloid deposits were immunopositive for lambda light chains and negative for kappa chains and AA protein. One was a known systemic lupus erythematosus patient with polyclonal hypergammaglobulinaemia. The other patient was found to have plasma cell dyscrasia with monoclonal IgG lambda gammopathy. Both patients did not develop systemic amyloidosis. In contrast, lung involvement in systemic AA amyloidosis was not obvious clinically or macroscopically but was histologically evident in 75% of cases subjected to autopsy. Amyloid was detected mainly in the walls of arterioles and small vessels, and along the alveolar septa. It was less frequently detected in the pleura, along the basement membrane of the bronchial epithelium and around bronchial glands. In one case of systemic AL amyloidosis associated with multiple myeloma, an "amyloidoma" occurred in the subpleural region reminiscent of localized amyloidosis. These cases pose questions on (1) whether localized "tumour-like" amyloidosis is a *forme fruste* of systemic AL amyloidosis and (2) the differing pattern of tissue deposition of different chemical types of amyloid fibrils, with the suggestion that light chain amyloid has a greater tendency to nodular deposition than AA amyloid.

*Key words:* Lung, amyloidoma, AL amyloid, AA amyloid, nodular amyloid.

### INTRODUCTION

Amyloid involvement of the lung is not often appreciated by histopathologists as biopsies for the diagnosis of systemic amyloidosis are traditionally taken from the rectum, kidney, liver, heart or abdominal fat and not from the respiratory tract. Hence, although the lung is known to be involved in both systemic and localized forms of amyloidosis, the pattern of amyloid infiltration in this organ, particularly in relation to the chemical form of amyloid fibril protein involved, has been poorly documented. This study undertakes to correlate the pattern of amyloid deposition in the lower respiratory tract with the physico-chemical classification of amyloidosis with the hope that further insight may be gained on the complex process of amyloidogenesis.

### MATERIALS AND METHODS

The cases included in this study were subjects

with histological material showing the presence of amyloid in the lower respiratory tract retrieved from the archives of the Department of Pathology, University of Malaya Medical Centre. These cases had been detected as a result of previous studies into the prevalence and patterns of amyloidosis in a Malaysian patient population served by the University of Malaya Medical Centre. The studies involved screening of Congo red-stained histological sections from (1) 27,052 routine biopsies (excluding products of conception and endometrial curettings) from 22,000 patients served by the Medical Centre over a 5.5 year period, (2) 377 consecutive autopsies on the Orang Asli (peninsular aborigines) and 37 consecutive autopsies of leprosy patients performed at this Medical Centre. Amyloid deposits were detected in 186 patients on the basis of the surgical biopsy screening process. Systemic AA amyloidosis was detected in 11 Orang Asli and 7 leprosy patients subjected to autopsy. The patterns of

amyloidosis in these cases have been described in previous publications.<sup>2,3</sup>

For all the cases, formalin-fixed, paraffin-embedded histology blocks of lower respiratory tract tissues were retrieved from the files. 4-µm-thick sections were stained with haematoxylin & eosin, alkaline Congo red, and alkaline Congo red after prior exposure to potassium permanganate. In addition, sections were stained using a standard immunoperoxidase method for immunoreactivity against AA protein, lambda light chains and kappa light chains.<sup>4</sup> The presence of amyloid was determined by the universal histological criteria of Congo-red positivity and apple-green birefringence. Amyloid deposits were considered to be AA in type if they were permanganate-sensitive and immunoreactive for AA protein.<sup>4</sup>

Clinical information on the subjects, with particular regard to the presence of systemic amyloidosis, plasma cell dyscrasias and immunological abnormalities, were obtained from clinical case records or autopsy records.

**RESULTS**

A total of 15 cases with histological evidence of amyloid involvement of the lower respiratory tract were detected from the screened archival material. Two were categorised as primary localized amyloidosis. Pulmonary amyloidosis was also detected in 12 cases of systemic AA amyloidosis (6 Orang Asli and 6 leprosy) and 1 patient with systemic AL amyloidosis. A comparison of their tinctorial and morphological characteristics is charted in Table 1.

*Primary localized amyloidosis of the lung*

The two cases detected were 2 (28.6%) of 7 localized nodular amyloidosis involving various organs obtained from the screened archives. In both, there was no evidence of systemic amyloidosis. One was a 38-year-old Chinese female who was known to suffer from systemic lupus erythematosus. Investigations into the complaint of cough with haemoptysis revealed a mass in the left main bronchus. A neoplasm, possibly malignant, was considered. The excised specimen revealed an endobronchial mass of amyloid material closely associated with an infiltrate of plasma cells, lymphocytes and occasional multinucleated giant cells (Fig. 1). The amyloid material was permanganate-resistant, immunonegative for AA protein and kappa light chains and immunoreactive for lambda light chains. Associated plasma cells were immunoreactive for lambda light chains and negative for kappa chains. Serum protein electrophoresis revealed a polyclonal hypergammaglobulinaemia.

The second patient was a 64-year-old Chinese man who presented with cough and dyspnoea. Investigations revealed a right pleural effusion and a right lung mass. This was excised on a clinical suspicion of neoplasia. Histology revealed nodular amyloid deposits in the lung parenchyma (Fig. 2) closely associated with the presence of multinucleated giant cells, plasma cells and lymphocytes. No amyloid was detected in the alveolar septa although occasionally the amyloid deposits encircled blood vessels. The amyloid material was permanganate-resistant,

**TABLE 1: Comparison of the morphological and staining characteristics of various categories of pulmonary amyloidosis**

	<i>Primary localized</i>	<i>Systemic AA</i>	<i>Systemic AL</i>
Gross appearance	Mass	Not obvious; diffuse	Mass
Presence of :			
Plasma cells	+		+
Giant cells	+		+
Involvement of:			
Blood vessels	+/-	+	-
Alveolar septa		+	
Permanganate reaction	Resistant	Sensitive	Resistant
AA protein	Negative	Positive	Negative
Lambda chains	Positive	Negative	Negative
Kappa chains	Negative	Negative	Negative

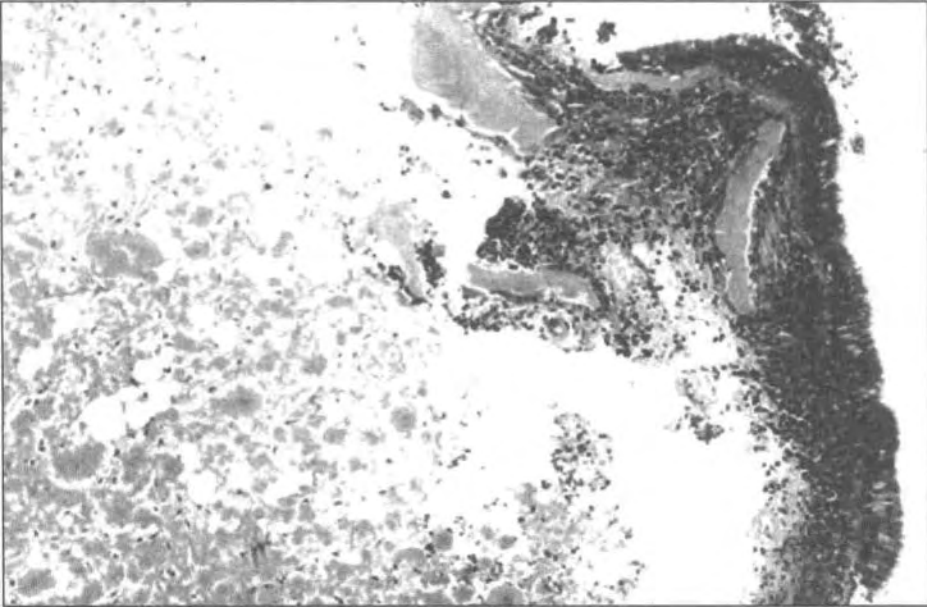


FIG. 1: Amorphous eosinophilic deposits of amyloid beneath the respiratory mucosa in a case of localized amyloidosis (tracheobronchial pattern). Note the presence of large numbers of plasma cells. H&E  $\times 150$ .

immunonegative for AA protein and kappa light chains and **immunoreactive** for lambda light chains. Associated plasma cells were immunoreactive for lambda light chains and negative for kappa chains. Serum protein electrophoresis revealed a monoclonal IgG lambda gammopathy. However, no myeloma or systemic amyloidosis was detected.

#### *Systemic AA amyloidosis involving lung*

11 Orang Asli and 7 leprosy subjects showed evidence of systemic AA amyloidosis on autopsy. Pulmonary material was available from 16 subjects (9 Orang Asli and 7 leprosy) for histological review. 12 (75%) of these showed amyloid involvement of the lower respiratory

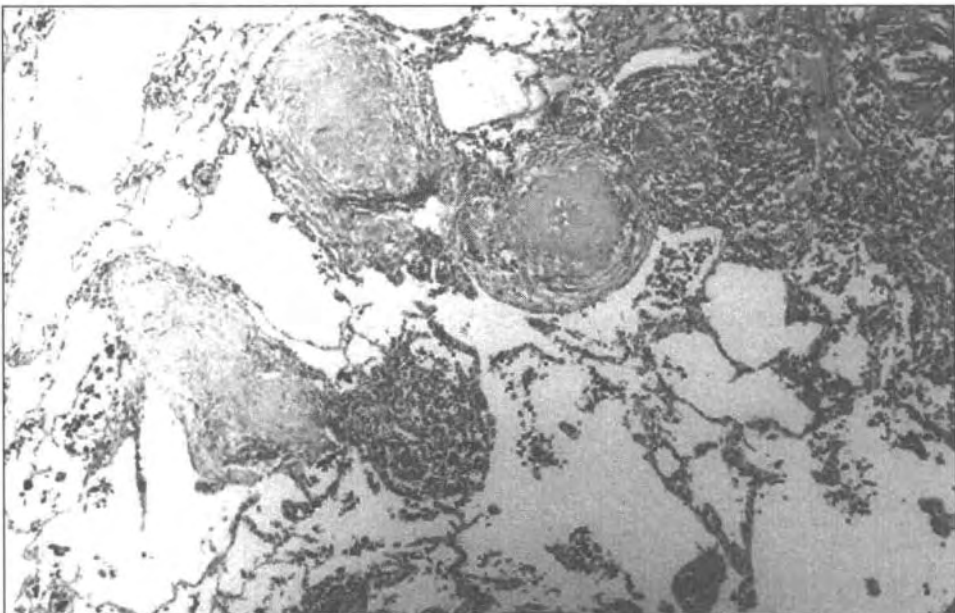


FIG. 2: Nodules of amyloid within the lung parenchyma in a case of localized pulmonary amyloidosis (nodular parenchymal pattern). There is no involvement of alveolar septa. H&E  $\times 150$ .

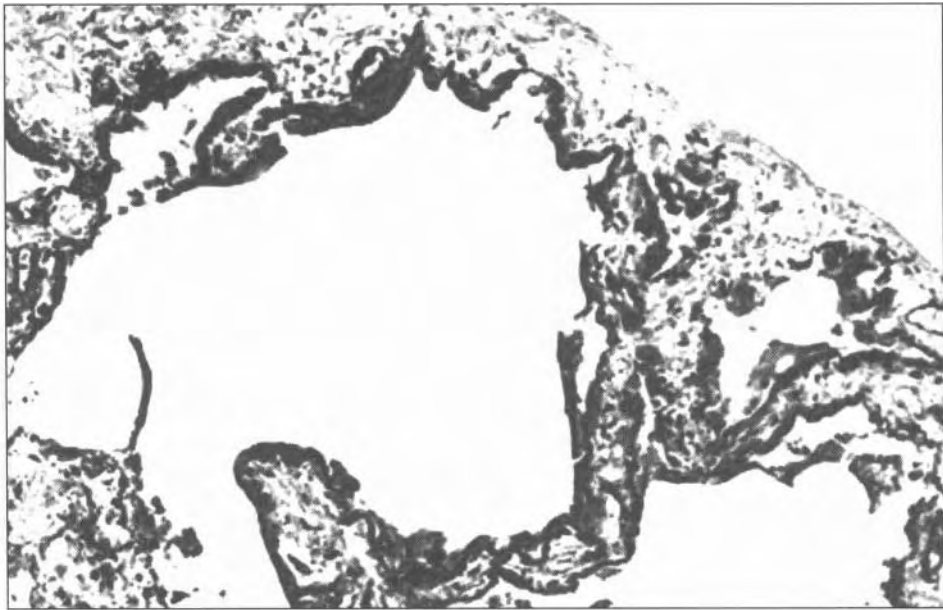


FIG. 3: Systemic AA amyloidosis with pulmonary involvement. Amyloid deposits line the alveolar walls, exhibiting a diffuse alveolar septal pattern. Immunoperoxidase against AA protein  $\times 200$ .

tract. 6 were Orang Asli subjects with evidence of tuberculosis while the remaining 6 were leprosy patients with long-standing lepromatous leprosy. In all these cases, amyloid involvement of the lung did not result in any clinical manifestations or gross findings at autopsy. However, amyloid deposition was obvious

histologically along alveolar walls (Figs. 3 & 4) and surrounding bronchial glands (Fig. 5). The distribution of the deposits is shown in Table 2. The amyloid material was permanganate-sensitive and immunoreactive for AA protein. There was no associated inflammatory response.

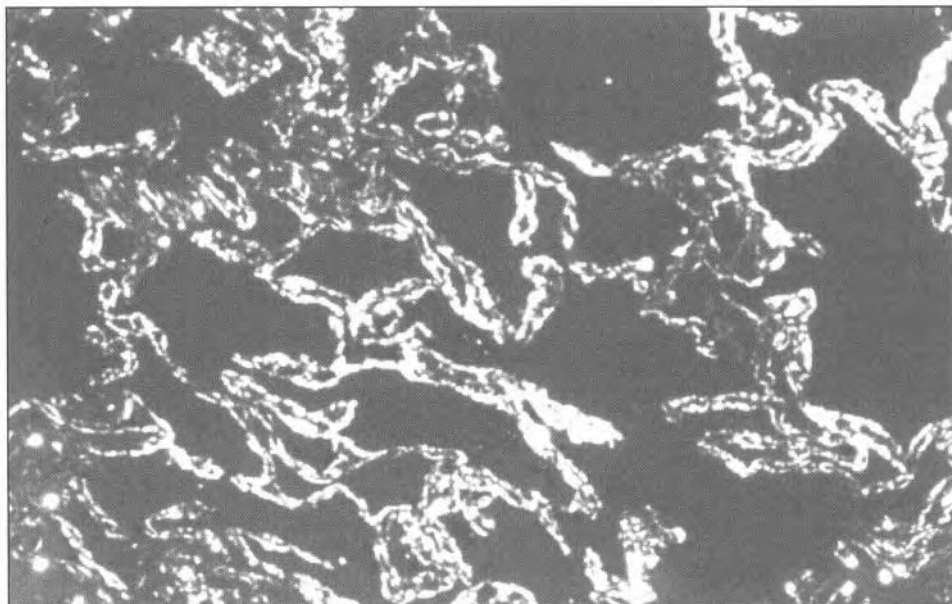


FIG. 4: Systemic AA amyloidosis with diffuse alveolar septal pulmonary involvement. Birefringent amyloid deposits are seen along the alveolar septa. Congo red under cross polarized light  $\times 150$ .

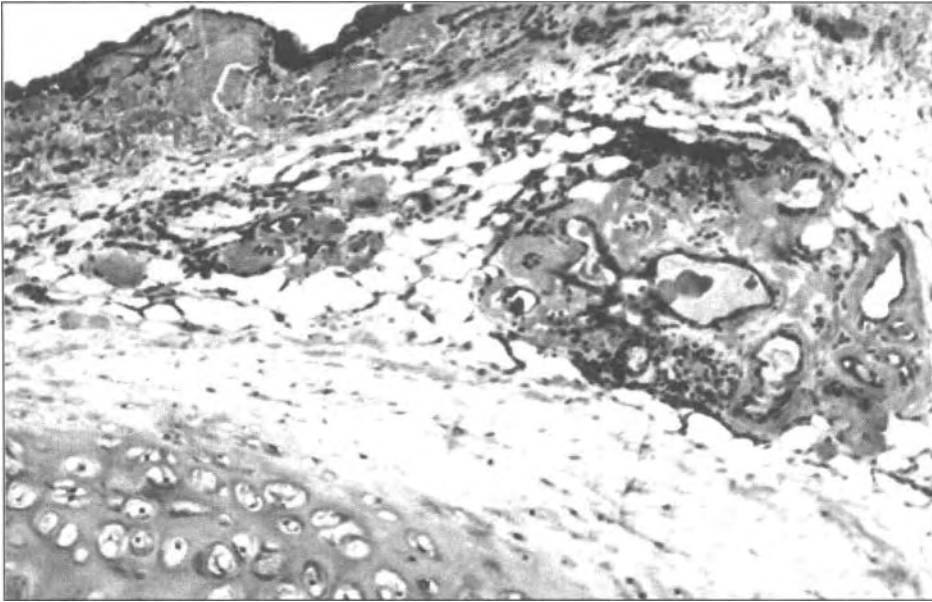


FIG. 5: Systemic AA amyloidosis with amyloid deposits along the basement membrane of bronchial epithelium and surrounding bronchial glands. H&E x 150.

*Systemic AL amyloidosis involving lung*

There was one instance of pulmonary involvement as part of the spectrum of systemic AL amyloidosis. The patient was a 43-yr-old Chinese man with Bence-Jones proteinuria, multiple osteolytic bone lesions and proven multiple myeloma. He had histological evidence

of amyloid involvement of the rectum, tongue, skin and bone marrow. Investigation of dyspnoea revealed a right subpleural lung mass. This was excised and histological examination revealed an amyloid mass associated with an infiltrate of plasma cells and multinucleated giant cells (Fig. 6). There was no amyloid deposition along

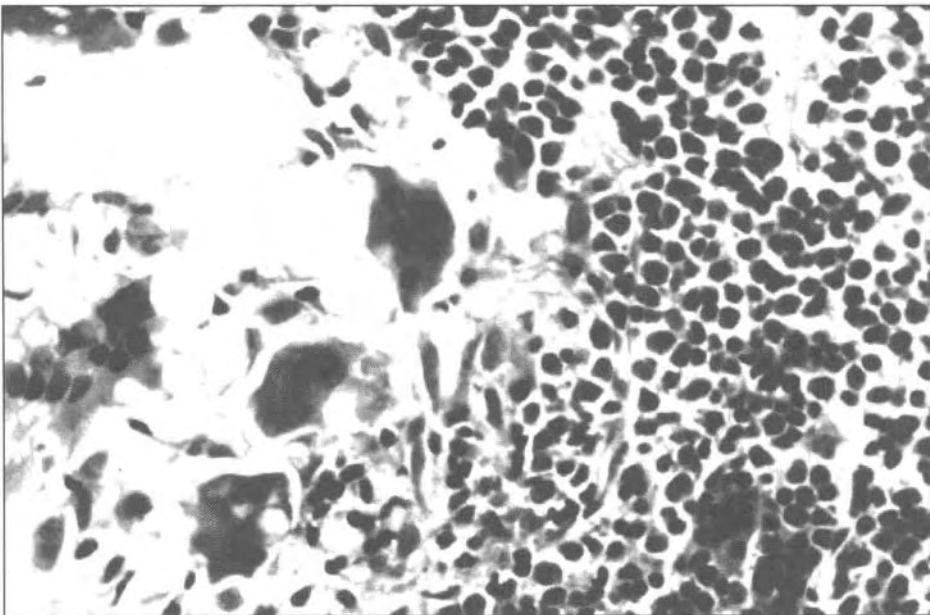


FIG. 6: Systemic AL amyloidosis. Amyloid deposits are associated with multinucleated giant cells and a heavy infiltrate of plasma cells. H&E x 350.

**TABLE 2: Location of amyloid infiltration in the lower respiratory tract in 12 cases of systemic AA amyloidosis**

Location	Prevalence
Arterioles	83%
Arteries	58%
Veins	17%
Alveolar septa	75%
Pleura	17%
Around bronchial glands	8%

alveolar septa, blood vessels or bronchiolar epithelia. The amyloid material was permanganate-resistant and immunonegative for AA protein, lambda and kappa light chains. Associated plasma cells were immunoreactive for lambda chains and negative for kappa chains.

## DISCUSSION

Amyloidosis of the lower respiratory tract is an uncommon phenomenon in histopathological practice. Most documented information is based on episodic case reports. The known patterns of pulmonary amyloidosis is summarized in Table 3. Three patterns of amyloidosis confined to the lung (pulmonary localized amyloidosis) are recognised. *Tracheobronchial amyloidosis* is the most common form of primary localized pulmonary amyloidosis.<sup>5</sup> Amyloid nodules or plaques occur in large airways as submucosal amyloid masses. A giant cell reaction is usual as is the associated presence of plasma cells and lymphocytes. The amyloid material is usually AL lambda in type. Most patients present with obstructive manifestations such as cough (74%), dyspnoea (60%), and hemoptysis (51%).<sup>6</sup> The first patient described in this study showed a pattern consistent with this form of amyloidosis.

**TABLE 3: Patterns of amyloidosis of the lung**

### *Primary localised amyloidosis*

Tracheobronchial amyloidosis  
Nodular parenchymal amyloidosis  
Diffuse parenchymal (alveolar septal) amyloidosis

### *Pulmonary involvement in systemic amyloidosis*

Any or all of above patterns

### *Pulmonary involvement in senile amyloidosis*

Alveolar-septal and vascular

The second pattern of localized pulmonary amyloidosis, known as "*nodular parenchymal amyloidosis*," is characterized by circumscribed "amyloidoma(s)" in the lung parenchyma, with occasional interstitial and perivascular extension.<sup>7</sup> Again, a giant cell reaction and associated presence of plasma cells and lymphocytes is usual. The amyloid tends to be AL lambda in type. Clinically, the lesion resembles a neoplasm. The usual manifestations are cough (30%), dyspnoea (12%) and hemoptysis (4%).<sup>6</sup> The second patient described conforms to this pattern both clinically and pathologically.

Localized pulmonary amyloidosis has also been described to assume a "*diffuse alveolar septal*" pattern. This is rare, resulting in a restrictive lung disease manifesting as dyspnoea (100%) and cough (100%).<sup>6</sup> Hemoptysis is not usual. The disease is progressive and often fatal. The lungs appear pale and firm at autopsy. There is thickening of alveolar septa by amyloid. Plasma cells and histiocytes may be present. Since the lung is diffusely involved, systemic amyloidosis must be excluded before the disease can be categorized as a localized form of pulmonary amyloidosis.<sup>7</sup>

Pulmonary involvement in systemic amyloidosis is known to take on a variety of patterns.<sup>6,8</sup> Amyloid is usually widespread and detectable in alveolar walls, vessels, airways and the pleural, resulting in variable symptomatology. However, localized masses have also been described. In this study, all the cases of systemic AA amyloidosis showed a pattern reminiscent of diffuse alveolar septal amyloidosis. However, pulmonary involvement in a case of systemic AL amyloidosis resembled the "nodular parenchymal" pattern.

No instances of senile amyloidosis was encountered in this study. This is not unexpected as the aged is poorly represented in the screened material.'

Although the numbers are too small for statistical calculations, the similarity in pulmonary involvement encountered in primary localized and systemic AL amyloidosis in this study, is nevertheless noteworthy. Both manifested as mass lesions closely associated with an infiltrate of plasma cells and giant cells. The amyloid deposits were light chain in chemical type (i.e. AL amyloid) and the associated plasma cell infiltrate appeared to be monoclonal and expressing lambda light chains. Clinically, these mass lesions were symptomatic (cough, hemoptysis or dyspnoea). In contrast,

none of the deposits of AA type manifested as mass lesions. None were associated with plasma cells or giant cells. AA amyloid infiltration appeared to be an insidious one without obvious clinical symptoms. These observations raise the question of whether localized AL amyloidosis is a forme *fruste* of systemic AL amyloidosis. Since the source of the amyloid fibrils in both localized and systemic AL amyloid deposits would be the plasma cell, it would appear that both share a common pathogenetic pathway initiated by plasma cell abnormalities. Localized tracheobronchial and nodular pulmonary amyloidosis may be regarded as a manifestation of localized clones of plasma cells (or plasmacytomas) while systemic AL amyloidosis results from systemic proliferation of neoplastic plasma cells. The clonal restriction of plasma cells associated with the localized amyloid deposits observed in this study is in agreement with observations of other workers who have raised the question of whether amyloid tumours of the lung is a form of immunocytoma.<sup>9</sup> The experience of other workers suggest that localized nodular amyloidosis of the lung is a relatively benign disease whereas the long-term outcome in patients with systemic amyloidosis is poor.<sup>10</sup>

The first patient described in this study is worthy of note because the development of amyloidosis in systemic lupus erythematosus (SLE) is known to be inordinately rare,<sup>11</sup> presumably because the pathophysiology of SLE involves T-cells rather than plasma cells. Furthermore, pulmonary involvement in systemic lupus erythematosus usually takes on an alveolar-septal pattern, unlike the tracheobronchial pattern observed here.

Although the association of giant cells with AL amyloid deposits is well documented, its role remains unresolved. Recent studies have raised the possibility that giant cells participate in amyloid fibril formation by uptake and modification of precursor light chains.<sup>12</sup> On the other hand, they may be part of a foreign body giant cell response to the inert amyloid material. The conspicuous absence of giant cells among AA amyloid deposits would not favour the later hypotheses.

#### ACKNOWLEDGEMENT

This study was supported by an IRPA research grant from the Malaysian Ministry of Science, Technology and the Environment on "Novel

amyloidosis proteins and patterns in Malaysians;" 06-02-03-0182.

#### REFERENCES

1. Looi LM. The pattern of amyloidosis in a Malaysian patient population. *Histopathology* 1991; 18: 133-41.
2. Looi LM, Prathap K. Amyloidosis in the Malaysian Aborigines (Orang Asli). *Pathology* 1979; 11: 575-82.
3. Looi LM, Jayalakshmi P, Lim KJ, Rajagopalan K. An immunohistochemical and morphological study of amyloidosis complicating leprosy in Malaysian patients. *Ann Acad Med Singapore* 1988; 17: 573-8.
4. Looi LM. An investigation of the protein components of amyloid using immunoperoxidase and permanganate methods on tissue sections. *Pathology* 1986; 18: 137-40.
5. Rubinow A, Celli BR, Cohen AS, Rigden BG, Bridy JS. Localized amyloidosis of the lower respiratory tract. *Am Rev Respir Dis* 1978; 118: 603-11.
6. Hasleton PS, editor. *Spencer's Pathology of the lung*. 5<sup>th</sup> ed. International Edition: McGraw-Hill; 1996. Pp 776-783.
7. Lee SC, Johnson H. Multiple nodular pulmonary amyloidosis. A case report and comparison with diffuse alveolar-septal pulmonary amyloidosis. *Thorax* 1975; 30: 178-5.
8. Celli BR, Rubinow A, Cohen AS, Brody JS. Patterns of pulmonary involvement in systemic amyloidosis. *Chest* 1978; 74: 543-7.
9. Ihling C, Weirich G, Gaa A, Schaefer HE. Amyloid tumors of the lung - an immunocytoma? *Pathol Res Pract* 1996; 192: 446-52.
10. Utz JP, Swensen SJ, Gertz MA. Pulmonary amyloidosis. The Mayo Clinic experience from 1980 to 1993. *Ann Intern Med* 1996; 124: 407-13.
11. Nomura S, Kumagai N, Kanoh T, Uchino H, Kurihara J. Pulmonary amyloidosis associated with systemic lupus erythematosus. *Arthritis Rheum* 1986; 29: 680-2.
12. Olsen KE, Sletten K, Sandgren O, Olsson H, Myrvold K, Westermarck P. What is the role of giant cells in AL-amyloidosis? *Amyloid* 1999; 6: 89-97.