

## CASE REPORT

### Bone cement implantation syndrome

Razuin R, Effat O,\* Shahidan MN,\*\* Shama DV,\*\* and MFM Miswan\*\*\*

*Centre for Pathology Diagnostic and Research Laboratories, Faculty of Medicine, University Technology MARA, \*Institute of Medical Molecular Biotechnology, Faculty of Medicine, University Technology MARA, \*\*Department of Forensic Medicine, Hospital Sungai Buloh, Malaysia and \*\*\*Centre for Orthopaedics and Traumatology, Faculty of Medicine, University Technology MARA, Malaysia*

#### Abstract

Bone cement implantation syndrome (BCIS) is characterized by hypoxia, hypotension, cardiac arrhythmias, increased pulmonary vascular resistance and cardiac arrest. It is a known cause of morbidity and mortality in patients undergoing cemented orthopaedic surgeries. The rarity of the condition as well as absence of a proper definition has contributed to under-reporting of cases. We report a 59-year-old woman who sustained fracture of the neck of her left femur and underwent an elective hybrid total hip replacement surgery. She collapsed during surgery and was revived only to succumb to death twelve hours later. Post mortem findings showed multiorgan disseminated microembolization of bone marrow and amorphous cement material.

*Keywords:* Bone cement implantation syndrome, BCIS, microembolism, fracture

#### INTRODUCTION

Bone cement implantation syndrome (BCIS) is a poorly defined, rare and potentially fatal intra-operative complication occurring in patients undergoing cemented orthopaedic surgeries.<sup>1</sup> It is characterized by hypotension, hypoxaemia, cardiac arrhythmias, cardiac arrest, or a combination of these, leading to death in 0.6-1% of patients.<sup>2</sup>

BCIS was first reported in 1970,<sup>3</sup> ten years after the introduction of bone cement in hip arthroplasty surgery. The aetiology and pathophysiology of BCIS are not fully understood, however, several mechanisms have been proposed, involving the release of methyl methacrylate (MMA) cement monomer into the circulation following cementation. Other mechanisms such as histamine release, complement activation and endogenous cannabinoid-mediated vasodilatation have also been proposed.<sup>1,4</sup>

Most published case reports of BCIS are generally supported by clinical findings of patients' haemodynamic instability during and after operation, with no histological evidence. We report a case of BCIS confirmed by autopsy and histopathology examination.

#### CASE REPORT

A 59-year-old Indian lady had allegedly slipped and fallen in a sitting position in the bathroom of her house. She was admitted to hospital approximately three hours after the fall and was subsequently diagnosed to have a closed fracture of the neck of her left femur. She underwent total hip replacement surgery under combined spinal epidural anaesthesia. During the operation, upon completion of bone cementing, her heart rate suddenly dropped from 100 to 55 per minute, oxygen saturation fell to 76% and she became unresponsive. Intravenous adrenaline and atropine were immediately given, however, her blood pressure and heart rate continued to fall. The patient was immediately sedated and intubated. After completion of the surgery, she was transferred to the intensive care unit (ICU). However despite full inotropic support, she did not respond and passed away approximately twelve hours post procedure. An autopsy examination was subsequently performed.

#### Autopsy findings

On autopsy, the internal organs were fairly unremarkable except for a slight left ventricular

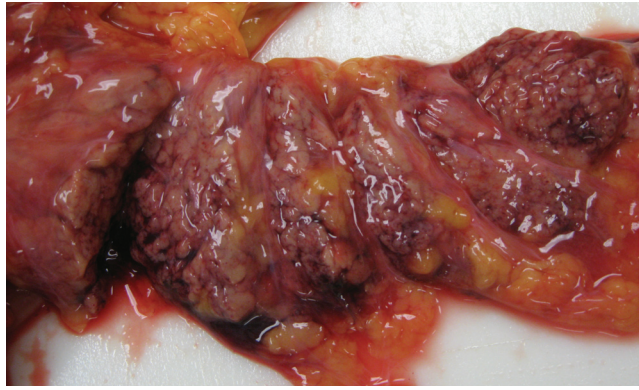

FIG. 1: Inflamed and haemorrhagic pancreas

hypertrophy. Minimal atheroma was noted within the middle segment of the right coronary artery. There was mild peritoneal effusion measuring 150 ml. An inflamed and haemorrhagic pancreas was noted (Figure 1).

*Histopathology findings*

Sections from the lungs showed bone marrow elements in the blood vessels, composed of fat admixed with haemopoietic precursor cells (Figure 2). The presence of fat was also

observed in the pulmonary sinusoids. In addition, neutrophils containing dark pigmented particles and amorphous material were observed in some of the blood vessels. The heart showed marrow elements adherent to the endocardium (Figure 3). Similar material (fat, marrow elements and amorphous material) were also seen within the blood vessels of the liver and kidneys. The pancreas showed acute inflammatory cell infiltrates, patchy areas of haemorrhage and necrosis and surrounding fat necrosis.

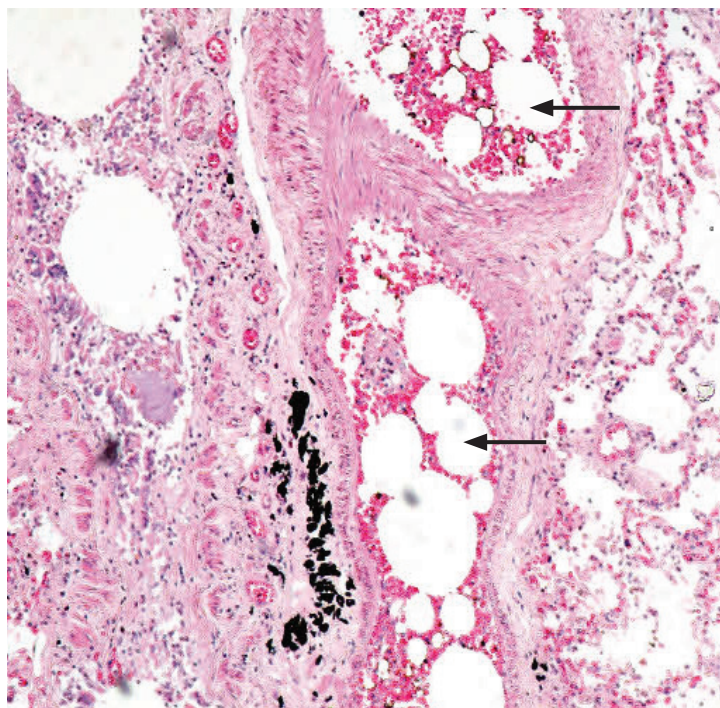


FIG. 2: Blood vessels in the lung showing fat embolisation (arrow), foreign material which polarized under microscopy and neutrophils containing dark pigments.

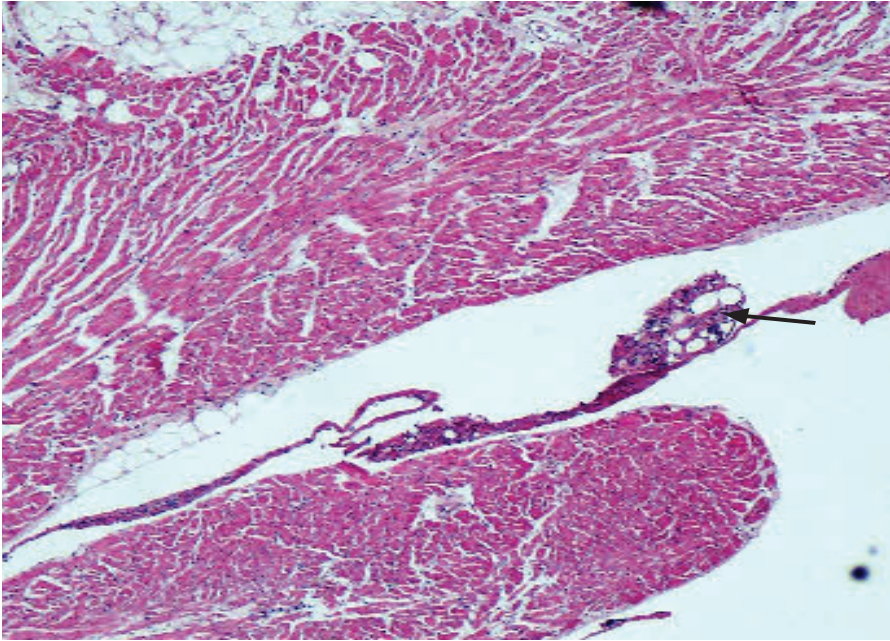


FIG. 3: Presence of bone marrow and fat emboli in the right ventricle of the heart (arrow)

The kidneys showed features of acute tubular necrosis.

The cause of death was disseminated microembolization as a consequence of hybrid total hip replacement surgery.

## DISCUSSION

Cardiovascular collapse associated with bone cement embolisation is a known complication of cemented arthroplasty procedure,<sup>1</sup> although fatality is rare.<sup>5,6</sup> The patient in this case demonstrated the classical clinical findings of BCIS: decrease in respiratory function, hemodynamic collapse and subsequent cardiac arrest. The diagnosis of BCIS was confirmed by histopathological examination of the various organs, which exhibited disseminated microembolization of medullary substances and amorphous material. Acute pancreatitis without fat necrosis denotes a fairly recent inflammation of the pancreas, most probably attributable to an acute ischaemic episode following cement implantation, as was acute tubular necrosis seen in the kidneys.

An experimental study in dogs demonstrated that cemented procedures were associated with more than 10-fold increase in the number of emboli compared to the uncemented group. In these animals, fat and marrow emboli are found in pulmonary microvasculature at post mortem.

Another recent animal study demonstrated that medullary lavage before cemented arthroplasty significantly reduced the number of emboli seen at post mortem in dogs.<sup>1</sup>

Post mortem examinations performed on patients who died following cemented arthroplasty showed emboli of bone marrow, fat, bone and MMA microparticles in the lungs.<sup>7</sup> Fat emboli have also been demonstrated at post mortem in the brain, kidneys and myocardium of a patient who had a cardiac arrest during insertion of the femoral prosthesis.<sup>1</sup>

Introduction of bone cement into the intra-medullary space during prosthesis insertion leads to increase in intra-medullary pressure, resulting in embolisation of fat, marrow elements, bone and cement particles.<sup>1</sup> The presence of these materials within the circulation cause release of histamines, complement activation and stimulates endogenous cannabinoid mediated vasodilation, manifesting as hemodynamic instability and collapse.<sup>1,4</sup>

Conclusion: The chronology of events, corroborated by autopsy and histopathology findings, point towards disseminated microembolization with eventual circulatory collapse and death, consistent with bone cement implantation syndrome. We have demonstrated the value of histopathological examination in confirming the diagnosis.

**REFERENCES**

1. Donaldson AJ, Thomson HE, Harper NJ, Kenny NW. Bone cement implantation syndrome. *Br J Anaesth.* 2009; 102 (1): 12-22.
2. Duncan JA. Intra-operative collapse or death related to the use of acrylic cement in hip surgery. *Anaesthesia.* 1989; 44(2): 149-53.
3. Powell JN, McGrath PJ, Lahiri SK, Hill P. Cardiac arrest associated with bone cement. *Br Med J.* 1970; 3(5718): 326.
4. Motobe T, Hashiguchi T, Uchimura T, *et al.* Endogenous cannabinoids are candidates for lipid mediators of bone cement implantation syndrome. *Shock.* 2004; 21(1): 8-12.
5. Mudgalkar N, Ramesh KV. Bone cement implantation syndrome: a rare catastrophe. *Anesth Essays Res.* 2011; 5(2): 240-2.
6. Govil P, Kakar PN, Arora D, *et al.* Bone cement implantation syndrome: a report of four cases. *Indian J Anaesth.* 2009; 53(2): 214-8.
7. Parvizi J, Holiday AD, Ereth MH, Lewallen DG. The Frank Stinchfield Award. Sudden death during primary hip arthroplasty. *Clin Orthop Relat Res.* 1999; (369): 39-48.