Malays J Pathol 2023; 45(2) : 271 – 273

CASE REPORT

Globus pharyngeus due to a lymphangiomatous polyp arising from the tonsil

Choo Xiang TAN[1], Sek Wee YEO[2], Yin Ping WONG[1,3]*, Geok Chin TAN[1,2,3]*

[1]Department of Pathology, Faculty of Medicine, Universiti Kebangsaan Malaysia; [2]Prince Court Medical Centre, Jalan Kia Peng, Kuala Lumpur, Malaysia; [3]Department of Laboratory Diagnostic Service, Hospital Canselor Tuanku Muhriz, Kuala Lumpur, Malaysia.

Abstract

Introduction: Lymphangiomatous polyp of the tonsil is generally accepted as a hamartomatous lesion. Its differential diagnosis includes fibroepithelial polyp, squamous papilloma, angiofibroma, haemangioma, arteriovenous malformation, hamartoma and lymphangioma. *Case report:* A 33-year-old man presented with 2 months history of feeling of foreign body sensation in the throat. Examination revealed a nodular red coloured polyp on the left tonsil. Histologically, the polyp was covered by squamous epithelium and is composed of numerous vascular channels containing lymphocytes and eosinophilic material, in a fibrous stroma. Immunohistochemically, the endothelial cells were positive toward CD31 and D2-40. *Discussion:* The characteristic histological features of a lymphangiomatous polyp are benign vascular proliferation with variable fibrous, adipose and lymphoid stromal components. Nested intraepithelial epidermotropism of lymphocytes can be observed. The vascular channels are typically thin-walled and contain eosinophilic proteinaceous material and lymphocytes. There is no reported incidence of recurrent or malignant transformation. (144 words)

Keywords: Tonsil, global pharyngeus, lymphangioma, hamartoma, polyp

INTRODUCTION

Tonsil is one of the routinely examined samples in histopathology. In our previous review, we discussed the non-neoplastic and neoplastic lesions of the tonsil.[1] Reactive follicular lymphoid hyperplasia is the predominant finding in most of the cases. Polyp arising from the tonsil is uncommon and the differential diagnosis include fibroepithelial polyp, squamous papilloma, angiofibroma, haemangioma, arteriovenous malformation, hamartoma and lymphangioma.[2,3] Here, we described a case of lymphagiomatous polyp of the tonsil in a 33-year-old man presented with foreign body sensation in the throat.

CASE REPORT

A 33-year-old man presented with 2 months history of feeling of foreign body sensation in the throat. He had a history of recurrent tonsillitis of about 2 to 4 times each year. There was neither pain nor itchiness. There was no significant past medical or surgical history. Examination revealed a nodular red coloured polyp on the left tonsil (FIG. 1). Intraoperatively, both tonsils were enlarged with a polyp at the inferior pole of the left tonsil. Examinations of the oral cavity, nasopharynx, and larynx were normal. Bilateral tonsillectomy was performed without complication and the he had an unremarkable post-operative course.

Histopathological examination showed a polyp arising from the surface of the tonsil. The polyp was soft, light brown and had a smooth surface. It measured 1.0 x 0.8 x 0.5 cm. Histologically, it was covered by squamous epithelium and is composed of numerous vascular channels containing lymphocytes and eosinophilic material, in a fibrous stroma (FIG. 2). Immunohistochemically, the endothelial cells were positive toward CD31 and D2-40 (FIG. 2). Histopathological examination findings are consistent with a lymphangiomatous polyp. At one week follow up, patient was well with no bleeding.

**Address for correspondence*: Geok Chin Tan (email: *tangc@ppukm.ukm.edu.my*) and Yin Ping Wong (*ypwong@ppukm.ukm.edu.my*), Department of Pathology, Faculty of Medicine, Universiti Kebangsaan Malaysia, Jalan Yaacob Latif, Bandar Tun Razak, Kuala Lumpur. Malaysia. Tel: +603- 6145 5362

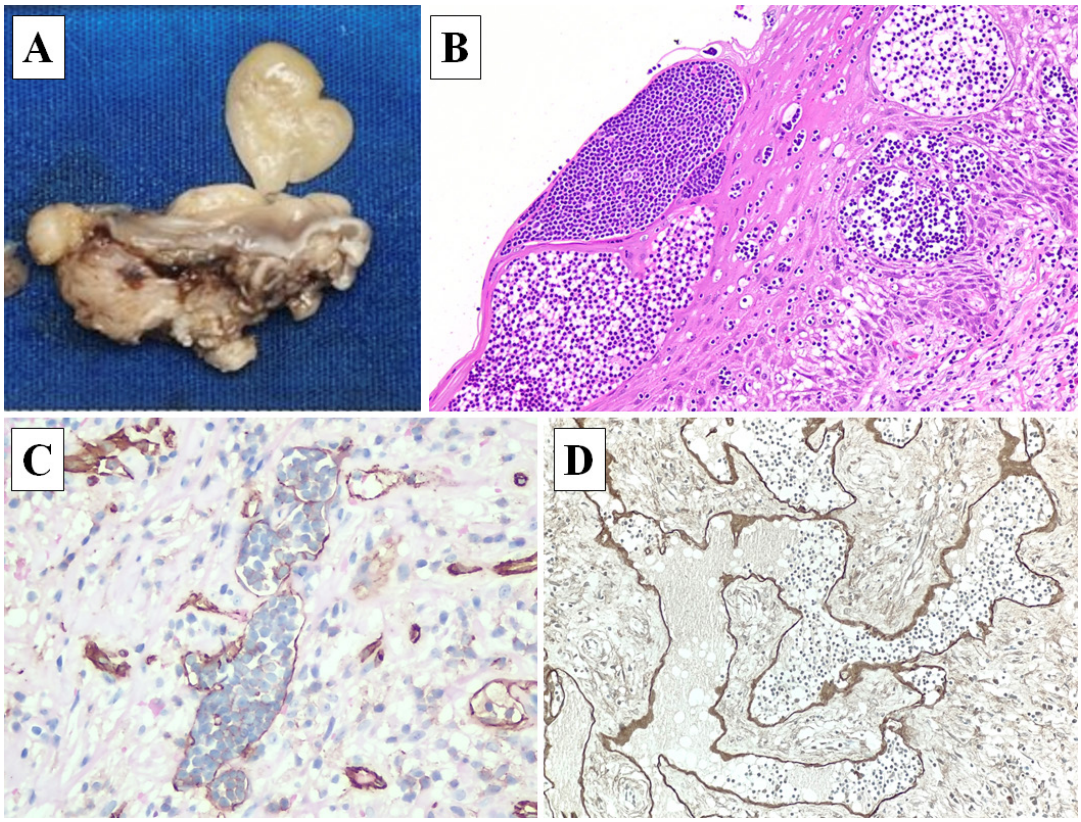

FIG. 1: (A) A light brown pedunculated polyp with smooth surface arising from the tonsil. B) The polyp composed of numerous vascular channels filled with lymphocytes. The vascular endothelial cells are positive towards both CD31 (C) and D2-40 (D).

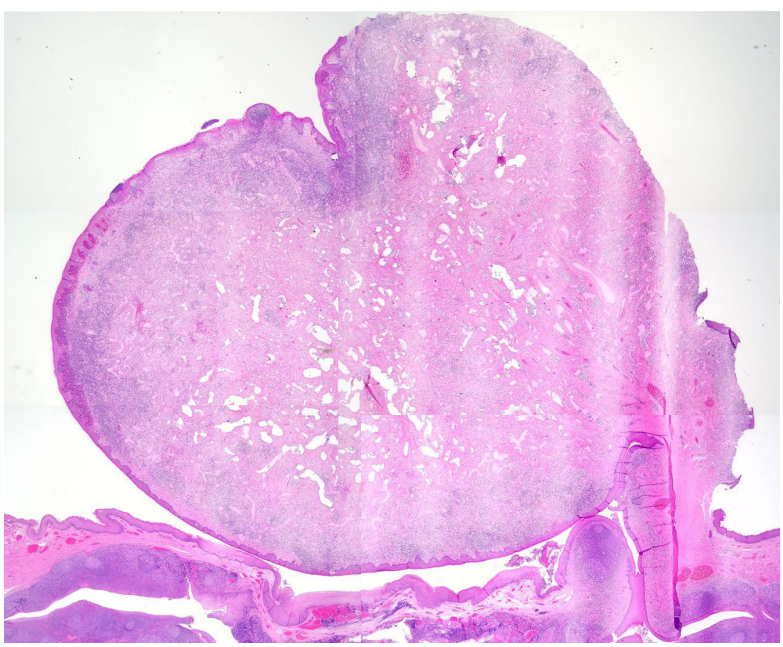

FIG. 2: Histologically, the polyp consists of numerous proliferative vascular channels and is attached to the tonsil by a pedunculated stalk.

DISCUSSION

Lymphangiomatous polyp is a hamatomatous lesion composed of numerous, dilated lymphatic channels in a fibrous, lymphoid and/or adipose stroma. It has been reported with various terms such as hamatomatous polyp of the tonsil, angiofibrolipoma, lymphangiomatous tonsillar polyp and lymphangiectatic fibrous polyp.[4] In a report of a case series of 26 patients, the mean age at presentation was 25 years old. The clinical presentations include foreign body sensation in the throat, sore throat, dysphagia and dyspnea.[2] It may also present as choking sensation, coughing and/ or vomiting. As the polyp is usually unilateral, a clinical suspicion of malignancy is expected.

The characteristic histological features of a lymphangiomatous polyp are benign vascular proliferation with variable fibrous, adipose and lymphoid stromal components. Nested intraepithelial epidermotropism of lymphocytes can be observed. The vascular channels are typically thin-walled and contain eosinophilic proteinaceous material and lymphocytes. CD31 and D2-40 immunohistochemistry are markers for vascular endothelial cells and lymphatic endothelial cells, respectively and both will highlight the lymphatic channels. These markers are useful in the exclusion of haemangioma and arteriovenous malformation. Lymphangiomatous polyp needs to be differentiated from the juvenile angiofibroma as the latter has a more aggressive course. They occur at the same range of age group. However, juvenile angiofibroma is usually located in the nasopharynx.

The pathogenesis of lymphagiomatous is still uncertain. The proposed mechanisms were 1) As most cases were seen in young adults or children, it might be an isolated hamartomatous lesion. 2) Chronic inflammation of the tonsil resulting in obstruction of the lymphatic channels; however, the incidence of lymphagiomatous polyp is so uncommon in comparison with chronic tonsillitis. 3) Dysregulation of growth hormone involved in lymphogenesis such as VEGF and Prox-1.[2,4-6] Finally, it could be multifactorial due to a combination of the abovementioned mechanisms. Because of the lack of understanding its pathogenesis, there is lack of standardization of the terminology used for this lesion in the literature. Notably, the 5th edition of the WHO classification of Head and Neck tumours uses the term "tonsillar hamartomatous polyp". Most authors support the hamartoma nature of this lesion, as lymphatic is tissue element normally found in tonsil. However, we wonder why the lymphatic element is the predominant proliferating component if it is a hamartomatous lesion. Further study is required to properly characterise this lesion, as to whether it should be considered as a lymphagiomatous polyp or a hamartomatous polyp?

In summary, excision of the polyp is needed to exclude other more aggressive lesions. Complete excision of the polyp together with the tonsil is the treatment of choice. There is no reported incidence of recurrent or malignant transformation post excision in previous reported cases. The actual incidence of lymphagiomatous/ hamartomatous polyp may be higher due to under-reporting and lack of standardization of the term used for this lesion.

Acknowledgements: We thank Datuk Dr Kuljit Singh (Chief Medical Office), Prince Court Medical Centre for allowing us to publish this case.

Authors' contribution: All authors have contributed to the drafting and approval of the manuscript.

Conflict of interest: The authors declare no conflict of interest.

REFERENCES

1. Tan GC, Stalling M, Al-Rawabdeh S, Kahwash BM, Alkhoury RF, Kahwash SB. The spectrum of pathological findings of tonsils in children: A clinicopathological review. Malays J Pathol. 2018;40(1):11-26.
2. Kardon DE, Wenig BM, Heffner DK, Thompson LD. Tonsillar lymphangiomatous polyps: a clinicopathologic series of 26 cases. Mod Pathol. 2000;13(10):1128-33.
3. Min HJ, Kim KS. Lymphangiomatous Polyp Arising From the Palatine Tonsil. Ear Nose Throat J. 2021;100(3):NP154-5.
4. Goulioumis A, Gkorpa M, Kekempanou K, Kourelis K. Hamartomatous polyp of the palatine tonsil: histological considerations and review of the literature. BMJ Case Rep. 2023;16(5):e254536.
5. Park E, Pransky SM, Malicki DM, Hong P. Unilateral lymphangiomatous polyp of the palatine tonsil in a very young child: a clinicopathologic case report. Case Rep Pediatr. 2011;2011:451542.
6. do Amaral-Silva GK, Ribeiro-Brizola J, Santos ÁA, Cieslak-Sanches SR, Chicrala GM, Gaetti-Jardim EC, Antunes DM. Hamartomatous Polyp of the Palatine Tonsil: A Case Report and Critical Literature Review. Head Neck Pathol. 2023;17(2):502-8.