

ORIGINAL ARTICLE

Cyclooxygenase-2 (COX2) expression in adenocarcinoma surpasses that of squamous cell carcinoma in the uterine cervix

Ananth Kumar MARUTHA MUTHU MD, Phaik-Leng CHEAH MBBS, FRCPath, Cing-Chai KOH BSc, Man-Fong CHEW MBBS, MPath, Yen-Fa TOH MD, MPath and Lai-Meng LOOI FRCPA, FRCPath

Department of Pathology, Faculty of Medicine, University of Malaya, Kuala Lumpur, Malaysia

Abstract

Over the years, adenocarcinoma (ADC), which has a worse prognosis than squamous cell carcinoma (SCC) of the cervix, has shown an increasing trend. Cyclooxygenase-2 (COX2) expression which has been associated with worse prognosis in several solid cancers was studied for its association with SCC and ADC of the cervix. 35 histologically re-confirmed SCC and 35 ADC were immunohistochemically stained for COX2 using a mouse monoclonal antibody to COX2 (1:100; Dako: Clone CX-294) on a Ventana Benchmark XT. The histoscore was computed as intensity of staining, semi-quantitated on a scale of 0-3 with 0 = negative, 1 = weak, 2 = moderate and 3 = strong staining intensity; multiplied by percentage of immunopositivity on a scale of 0-4 with 0 = <1%, 1 = 1-25%, 2 = 26-50%, 3 = 51-75% and 4 = ≥75% of immunopositive tumour cells. Histoscore 1-3/12 was considered as low and ≥4/12 as high COX2 expression. SCC affected Chinese more than Malays, while Malays had more ADC (p = 0.032). Mean age at presentation of SCC (57.5 years) was about a decade later than ADC at 47.9 years (p = 0.002). 30/35 (85.7%) of SCC and 34/35 (97.1%) of ADC expressed COX2. Histoscores of ADC (median = 4.0, IQR = 3.0-6.0) was significantly higher (p = 0.014) than those of SCC (median = 3.0, IQR = 2.0-3.0). High histoscores (≥4/12) were more frequent in ADC (55.9%) compared with SCC (26.7%) (p = 0.018), implicating COX2, either directly or indirectly, as a possible player in influencing the poorer outcome of ADC compared with SCC.

Keywords: COX2, cervix, squamous cell carcinoma, adenocarcinoma

INTRODUCTION

Globally, cervical cancer is the third most common cancer in females and the fourth leading cause of cancer mortality among women.¹ Squamous cell carcinoma (~70%) is the major histological subtype of cervical carcinoma followed by adenocarcinoma (~20%) with rarer subtypes including adenosquamous and neuroendocrine carcinomas making up the rest.² While squamous cell carcinoma (SCC) has shown a decreasing trend, adenocarcinoma (ADC) has not, and appears to be steadily increasing over the years.³⁻⁵ This trend has also been recorded in an earlier study amongst Malaysians.⁶ Besides the increasing trend, more importantly, the rise of cervical adenocarcinoma translates into an increase of a histological type which fares less well than its squamous counterpart.⁷⁻⁹

Cyclooxygenase is a key enzyme that catalyses the conversion of arachidonic

acid to prostaglandins and has 2 isoforms, cyclooxygenase-1 (COX1) and cyclooxygenase-2 (COX2).¹⁰ COX1 is present in normal tissues and participates in physiological processes while COX2 is generally not found under normal circumstances but can be induced by cytokines, growth factors, bacterial endotoxins and tumour promoters¹¹ and involves itself in tumour progression through regulating cell proliferation, apoptosis, immune surveillance, angiogenesis and cell adhesion via prostaglandin E2.^{12,13} Although COX2 expression has been shown in several solid tumours including those of the breast, lung, liver, pancreas, colorectum¹⁴ etc., with reports of negative impact on prognosis and worse outcome for cancers which express COX2,¹⁵⁻¹⁸ work on cervical cancers remains few. Bearing this in mind, we initiated a study to determine the expression of COX2 in cervical carcinoma. Taking into account the generally poorer expected

Address for correspondence: Dr Ananth Kumar Marutha Muthu, Department of Pathology, Faculty of Medicine, University of Malaya, 50603 Kuala Lumpur, Malaysia. E-mail: ananth.kumar@ummc.edu.my

outcome of ADC compared with SCC we were also interested to determine whether expression of COX2 is differentially elevated in these two histological types.

MATERIALS AND METHODS

Thirty-five consecutive cases of cervical SCC and cervical ADC respectively, histologically diagnosed for the first time from 31 December 2012 backwards, at the Department of Pathology, University of Malaya Medical Centre (UMMC), were retrieved from a cohort identified from another ongoing study by the authors. All the slides of the cases were histologically reviewed and only re-confirmed cases were admitted. A paraffin block of the formalin-fixed cervical SCC and ADC was selected during the review for immunohistochemical staining and only blocks that had sufficient tissue remaining for future review, after sectioning for this study, were finally cut. One 4-µm section from each case was cut on to a platinum coated slide (Matsunami Glass Industries, Japan) for immunohistochemical staining with a mouse monoclonal antibody to COX2 (1:100; Dako: Clone CX-294) using a Ventana Benchmark XT automated system. A case of breast carcinoma previously tested positive for COX2 served as a positive control and was run with each batch.

COX2, expressed in the cytoplasm of the tumour cells, was semi-quantitated for intensity of staining on a scale of 0-3, with 0 = negative, 1 = weak, 2 = moderate and 3 = strong staining as well as for percentage of tumour cells stained on a scale of 0-4, with 0 = <1%, 1 = 1-25%, 2 = 26-50%, 3 = 51-75% and 4 = ≥75% of tumour cells expressing COX2. The histoscore was computed as the intensity of staining multiplied by the percentage of immunopositive tumour cells, and ranged from 0-12.¹⁶ Histoscore of 1-3/12 would be considered as low COX2 expression,

while ≥4/12 would be considered as high COX2 expression.

Statistical analysis was carried out using Pearson’s chi-square test and Mann-Whitney U test on SPSS version 23 (SPSS, Chicago). Statistical significance was set at $p \leq 0.05$.

Approval for the study was granted by the UMMC Medical Research Ethics Committee (MECID.NO: 2015111883).

RESULTS

In the SCC group, the Malays formed 22.9%, Chinese 42.9%, Indians 20.0% of the cohort while in the ADC group, the Malays formed 48.6%, Chinese 25.7%, Indians 14.3% of the cases studied. The ethnic origins were not clearly defined in 5 and 4 cases of SCC and ADC respectively. For the two major Malaysian ethnic groups, there was an increased preponderance of Chinese with SCC and Malays with ADC ($p = 0.032$). Age of patients with SCC ranged between 38-80 years with a mean ± SD of 57.5 ± 12.4 years which was almost a decade older than that of ADC with a range of 25-73 years and mean ± SD of 47.9 ± 12.0 years ($p = 0.002$). The demographic profile of the cases of cervical SCC and ADC is shown in Table 1.

Thirty of the 35 (85.7%) SCC and 34 (97.1%) of the 35 ADC demonstrated cytoplasmic expression of COX2 in their tumour cells (Fig. 1). The COX2 histoscores in SCC and ADC of the cervix are shown in Table 2. A histoscore range of 0-12 was recorded for both SCC and ADC cases with the histoscores of ADC (median = 4.0, interquartile range = 3.0-6.0) being significantly higher ($p = 0.014$) than those of SCC (median = 3.0, interquartile range = 2.0-3.0). On further subcategorization of the COX2 histoscores into low (1-3/12) and high (≥4/12) scores, high histoscores were expressed by SCC in 8 (26.7%) and low histoscores in 22 (73.3%) of the 30

TABLE 1: Demographic profile of the cervical squamous cell carcinoma (SCC) and adenocarcinoma (ADC) cases

		SCC (n = 35)	ADC (n = 35)
Ethnic group	Malay	8 (22.9%)	17 (48.6%)
	Chinese	15 (42.9%)	9 (25.7%)
	Indian	7 (20.0%)	5 (14.3%)
	Not available	5 (14.3%)	4 (11.4%)
Age (years)	Range	38-80	25-73
	Mean ± SD	57.5 ± 12.4	47.9 ± 12.0

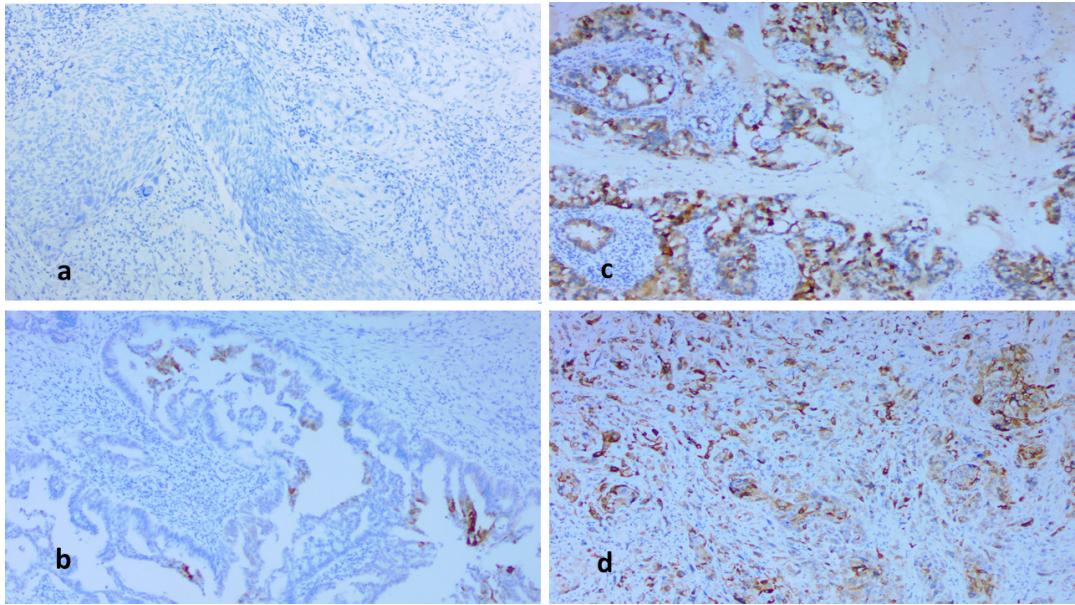


FIG. 1: (a) Case of cervical squamous cell carcinoma which shows no COX2 expression. (b) An adenocarcinoma with low COX2 histoscore (<4/12). (c) Adenocarcinoma and (d) squamous cell carcinoma with strong COX2 cytoplasmic staining and high histoscores ($\geq 4/12$) (x100 magnification)

positive cases. In contrast, ADC expressed high histoscores in 19 (55.9%) and low histoscores in 15 (44.1%) of the 34 positive cases. Hence, more cases of ADC expressed high histoscores compared with SCC ($p = 0.018$).

DISCUSSION

Although there appears to be an increased preponderance of Chinese in the SCC group and Malays in the ADC group, this observation requires further study on larger populations to entitle a proper conclusion to be made regarding ethnic predilection. Similar to some other

studies,^{19,20} the presentation of cervical ADC also occurred earlier than SCC in our cohort. However, it has to be borne in mind that there are also studies where patients with ADC are not shown to be younger than those with SCC at presentation.²¹

In our study, 85.7% of SCC and 97.1% of ADC showed some immunopositivity for COX2, while others have recorded rates ranging between 24%-100% in SCC²²⁻²⁴ and 55%-100% in ADC.²³⁻²⁵ The wide range of rates reported is not surprising as there is still a lack of standardisation in the interpretation of “immunopositivity” and this

TABLE 2: Cyclooxygenase-2 (COX2) expression in squamous cell carcinoma (SCC) and adenocarcinoma (ADC) of the cervix

Cyclooxygenase-2 histoscore	Squamous cell carcinoma (n = 35)	Adenocarcinoma (n = 35)	p value
Range	0-12	0-12	0.014
Median	3.0	4.0	
IQR	2.0-3.0	3.0-6.0	
Positive expression	30	34	0.018
Low histoscore (Score = 1-3)	22 (73.3%)	15 (44.1%)	
High histoscore (Score = 4-12)	8 (26.7%)	19 (55.9%)	

has always to be considered when making inferences. In this study, using a histoscore derived by multiplying the intensity of staining and the percentage of tumour cells expressing COX2, it was noted that ADC had significantly higher histoscores compared with SCC. Taking cognisance of the lack of uniformity in interpretation of “immunopositivity” and the various cut-offs employed by different workers,^{16,26-28} we decided to further stratify the cases of SCC and ADC which expressed COX2 into those with low histoscores (1-3/12) and those with high histoscores ($\geq 4/12$) to provide added insight into whether ADC do have higher COX2 expression compared with SCC. By doing so, we also tried to eliminate the possibility of low-level expression of COX2 which may occur as a result of other non-neoplastic processes e.g. inflammation, as while Nagai *et al*²⁹ report that COX2 is not expressed in normal cervixes, others have observed COX2 expression in normal cervixes.^{30,31} By stratification into 2 categories of histoscores, it was noted that ADC demonstrated high histoscores in 55.9% of cases while SCC expressed high histoscores in 26.7% ($p = 0.018$). Thus, it appears reasonable to conclude that COX2 is expressed in both SCC and ADC of the cervix, but more frequently in ADC compared with SCC, a finding which lends further support to the observations noted by others.^{23,29,32,33}

The finding of COX2 expression in both SCC and ADC of cervix implicates COX2's participation in these two common cervical cancers. COX2 expression has been associated with poorer outcome of cervical cancers.²³ The increased expression in ADC over SCC is important as it may indicate a role for COX2, whether directly or indirectly, in influencing the poorer outcome of ADC compared with SCC. This should provide impetus towards design of mechanistic approaches that may unravel the role of COX2 in both histological types that can eventually lead to unravelling of treatment targets.^{34,35}

ACKNOWLEDGEMENT

This study was funded by University of Malaya's research grants RG493-13HTM and PO038-2015B.

REFERENCES

1. Ferlay J, Soerjomataram I, Dikshit R, *et al*. Cancer incidence and mortality worldwide: sources, methods and major patterns in GLOBOCAN 2012. *Int J Cancer*. 2015; 136: E359-86.
2. Stoler M, Bergeron C, Colgan TJ. Chapter 7: Tumours of the uterine cervix. In: Kurman RJ, Carcangiu ML, Herrington CS, Young RH, editors. WHO classification of tumours of female reproductive organs. 4th ed. Lyon: IARC; 2014. p. 169-206.
3. Wang SS, Sherman ME, Hildesheim A, Lacey JV Jr, Devesa S. Cervical adenocarcinoma and squamous cell carcinoma incidence trends among white women and black women in the United States for 1976-2000. *Cancer*. 2004; 100: 1035-44.
4. Chung HH, Jang MJ, Jung KW, *et al*. Cervical cancer incidence and survival in Korea: 1993-2002. *Int J Gynecol Cancer*. 2006; 16: 1833-8.
5. Williams NL, Werner TL, Jarboe EA, Gaffney DK. Adenocarcinoma of the cervix: should we treat it differently? *Curr Oncol Rep*. 2015; 17: 17.
6. Cheah PL, Looi LM, Sivanesaratnam V. Recent trends in histological pattern of cervical carcinoma among three ethnic groups in Malaysia. *J Obstet Gynaecol Res*. 1999; 25: 401-6.
7. Galic V, Herzog TJ, Lewin SN, *et al*. Prognostic significance of adenocarcinoma histology in women with cervical cancer. *Gynecol Oncol*. 2012; 125: 287-91.
8. Eifel PJ, Burke TW, Morris M, Smith TL. Adenocarcinoma as an independent risk factor for disease recurrence in patients with stage IB cervical carcinoma. *Gynecol Oncol*. 1995; 59: 38-44.
9. Fujiwara K, Monk B, Devouassoux-Shisheboran M. Adenocarcinoma of the uterine cervix: why is it different? *Curr Oncol Rep*. 2014; 16: 416.
10. Smith WL, DeWitt DL, Garavito RM. Cyclooxygenases: structural, cellular, and molecular biology. *Annu Rev Biochem*. 2000; 69: 145-82.
11. Vane JR, Bakhle YS, Botting RM. Cyclooxygenases 1 and 2. *Annu Rev Pharmacol Toxicol*. 1998; 38: 97-120.
12. Tilley SL, Coffman TM, Koller BH. Mixed messages: modulation of inflammation and immune responses by prostaglandins and thromboxanes. *J Clin Invest*. 2001; 108: 15-23.
13. Greenhough A, Smartt HJ, Moore AE, *et al*. The COX-2/PGE2 pathway: key roles in the hallmarks of cancer and adaptation to the tumour microenvironment. *Carcinogenesis*. 2009; 30: 377-86.
14. Liu B, Qu L, Yan S. Cyclooxygenase-2 promotes tumor growth and suppresses tumor immunity. *Cancer Cell Int*. 2015; 15: 106.
15. Kim HS, Moon HG, Han W, *et al*. COX2 overexpression is a prognostic marker for Stage III breast cancer. *Breast Cancer Res Treat*. 2012; 132: 51-9.
16. Generali D, Buffa FM, Deb S, *et al*. COX-2 expression is predictive for early relapse and aromatase inhibitor resistance in patients with ductal carcinoma in situ of the breast, and is a target for treatment. *Br J Cancer*. 2014; 111: 46-54.
17. Kim NK, Park JK, Shin E, Kim YW. The combination of nuclear factor kappa B, cyclooxygenase-2 and vascular endothelial growth factor expression predicts poor prognosis in stage II and III colorectal cancer. *Anticancer Res*. 2014; 34: 6451-7.

18. Wang ZM, Liu J, Liu HB, Ye M, Zhang YF, Yang DS. Abnormal COX2 protein expression may be correlated with poor prognosis in oral cancer: a meta-analysis. *Biomed Res Int.* 2014; 2014: 364207.
19. Chen JL, Huang CY, Huang YS, *et al.* Differential clinical characteristics, treatment response and prognosis of locally advanced adenocarcinoma/adenosquamous carcinoma and squamous cell carcinoma of cervix treated with definitive radiotherapy. *Acta Obstet Gynecol Scand.* 2014; 93: 661-8.
20. Lee YY, Choi CH, Kim TJ, *et al.* A comparison of pure adenocarcinoma and squamous cell carcinoma of the cervix after radical hysterectomy in stage IB-IIA. *Gynecol Oncol.* 2011; 120: 439-43.
21. Nogueira-Rodrigues A, Ferreira CG, Bergmann A, de Aguiar SS, Thuler LC. Comparison of adenocarcinoma (ACA) and squamous cell carcinoma (SCC) of the uterine cervix in a sub-optimally screened cohort: a population-based epidemiologic study of 51,842 women in Brazil. *Gynecol Oncol.* 2014; 135: 292-6.
22. Dursun P, Yuce K, Usubutun A, Ayhan A. Cyclooxygenase-2 expression in cervical intraepithelial neoplasia III and squamous cell cervical carcinoma, and its correlation with clinicopathologic variables. *Int J Gynecol Cancer.* 2007; 17: 164-73.
23. Kim YB, Kim GE, Pyo HR, *et al.* Differential cyclooxygenase-2 expression in squamous cell carcinoma and adenocarcinoma of the uterine cervix. *Int J Radiat Oncol Biol Phys.* 2004; 60: 822-9.
24. Sales KJ, Katz AA, Davis M, *et al.* Cyclooxygenase-2 expression and prostaglandin E(2) synthesis are up-regulated in carcinomas of the cervix: a possible autocrine/paracrine regulation of neoplastic cell function via EP2/EP4 receptors. *J Clin Endocrinol Metab.* 2001; 86: 2243-9.
25. Lee JS, Choi YD, Lee JH, *et al.* Expression of cyclooxygenase-2 in adenocarcinomas of the uterine cervix and its relation to angiogenesis and tumor growth. *Gynecol Oncol.* 2004; 95: 523-9.
26. Balan R, Amălinei C, Giușcă SE, *et al.* Immunohistochemical evaluation of COX-2 expression in HPV-positive cervical squamous intraepithelial lesions. *Rom J Morphol Embryol.* 2011; 52: 39-43.
27. Czachorowski MJ, Amaral AF, Montes-Moreno S, *et al.* Cyclooxygenase-2 expression in bladder cancer and patient prognosis: results from a large clinical cohort and meta-analysis. *PLoS One.* 2012; 7: e45025.
28. Hassan HE, Mohamed AA, Bakhiet AO, Ahmed HG. Immunohistochemical expression of COX2 and iNOS in bladder cancer and its association with urinary schistosomiasis among Sudanese patients. *Infect Agent Cancer.* 2013; 8: 9.
29. Nagai N, Tian X, Mukai K, *et al.* Overexpression of cyclooxygenase-2 protein and its relationship to apoptosis in cervical carcinoma treated with neoadjuvant chemotherapy. *Int J Mol Med.* 2003; 12: 709-14.
30. Landen CN Jr, Mathur SP, Richardson MS, Creasman WT. Expression of cyclooxygenase-2 in cervical, endometrial, and ovarian malignancies. *Am J Obstet Gynecol.* 2003; 188: 1174-6.
31. Hammes LS, Tekmal RR, Naud P, *et al.* Up-regulation of VEGF, c-fms and COX-2 expression correlates with severity of cervical cancer precursor (CIN) lesions and invasive disease. *Gynecol Oncol.* 2008; 110: 445-51.
32. Bandyopadhyay R, Chatterjee U, Mondal SK, Nag D, Sinha SK. A study on expression pattern of cyclooxygenase-2 in carcinoma of cervix. *Indian J Pathol Microbiol.* 2011; 54: 695-9.
33. Gadducci A, Guerrieri ME, Greco C. Tissue biomarkers as prognostic variables of cervical cancer. *Crit Rev Oncol Hematol.* 2013; 86: 104-29.
34. Deshpande R, Mansara P, Kaul-Ghanekar R. Alpha-linolenic acid regulates Cox2/VEGF/MAP kinase pathway and decreases the expression of HPV oncoproteins E6/E7 through restoration of p53 and Rb expression in human cervical cancer cell lines. *Tumour Biol.* 2016; 37: 3295-305.
35. Li B, Li X, Xiong H, *et al.* Inhibition of COX2 enhances the chemosensitivity of dichloroacetate in cervical cancer cells. *Oncotarget.* 2017; 8: 51748-57.